



SEQUELLES D'ENTORSE DE CHEVILLE EN SCINTIGRAPHIE OSSEUSE

Nicolas DELEVAL

05/07/2019

Patient de 37 ans

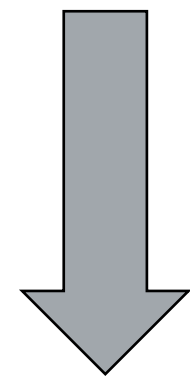
Entorse de cheville 6 mois auparavant avec traumatisme direct de la face externe de la cheville

Douleur sus-malléolaire circonférentielle après 5 mois de course à pied

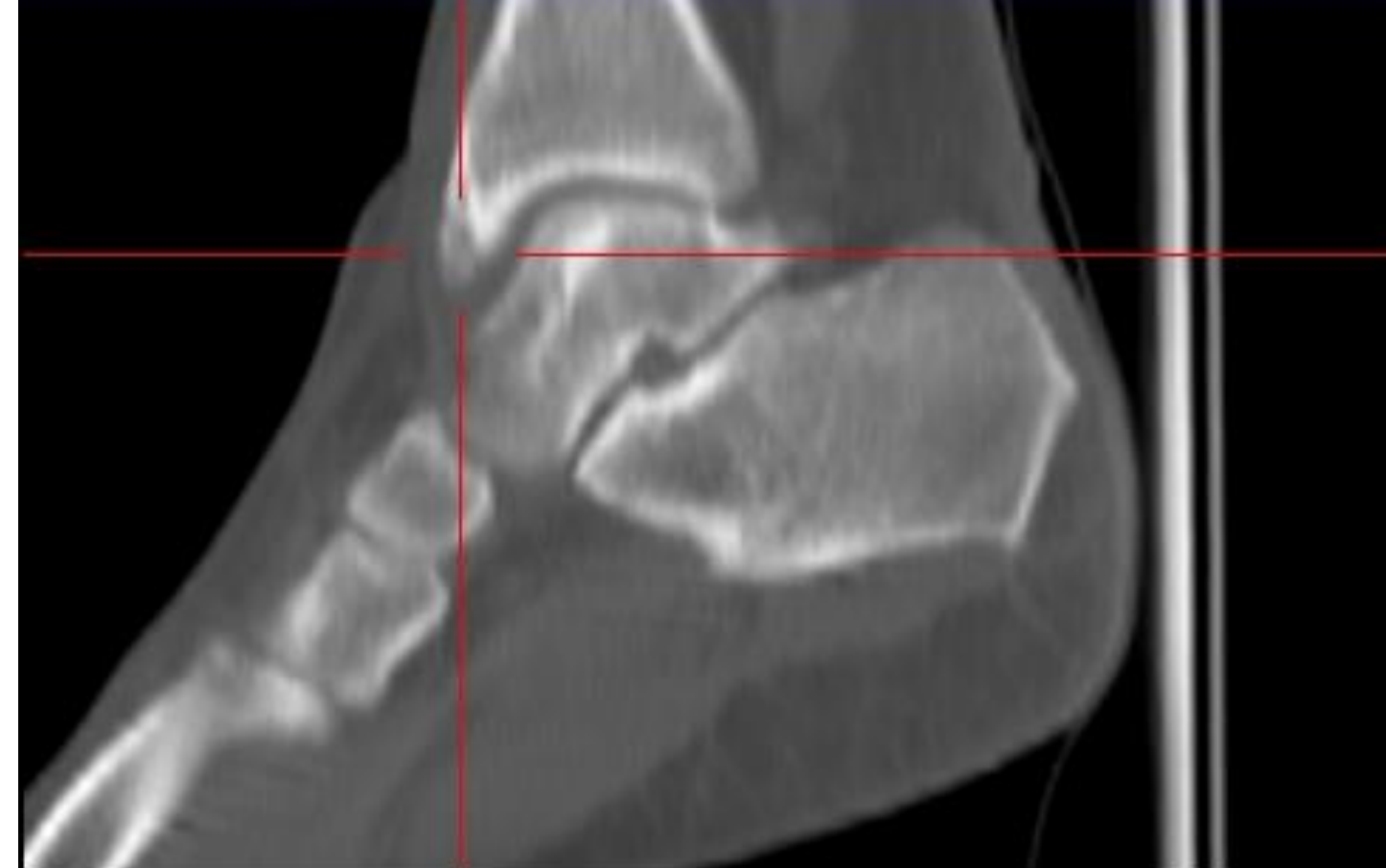
Examen clinique non contributif

CHEVILLE DROITE

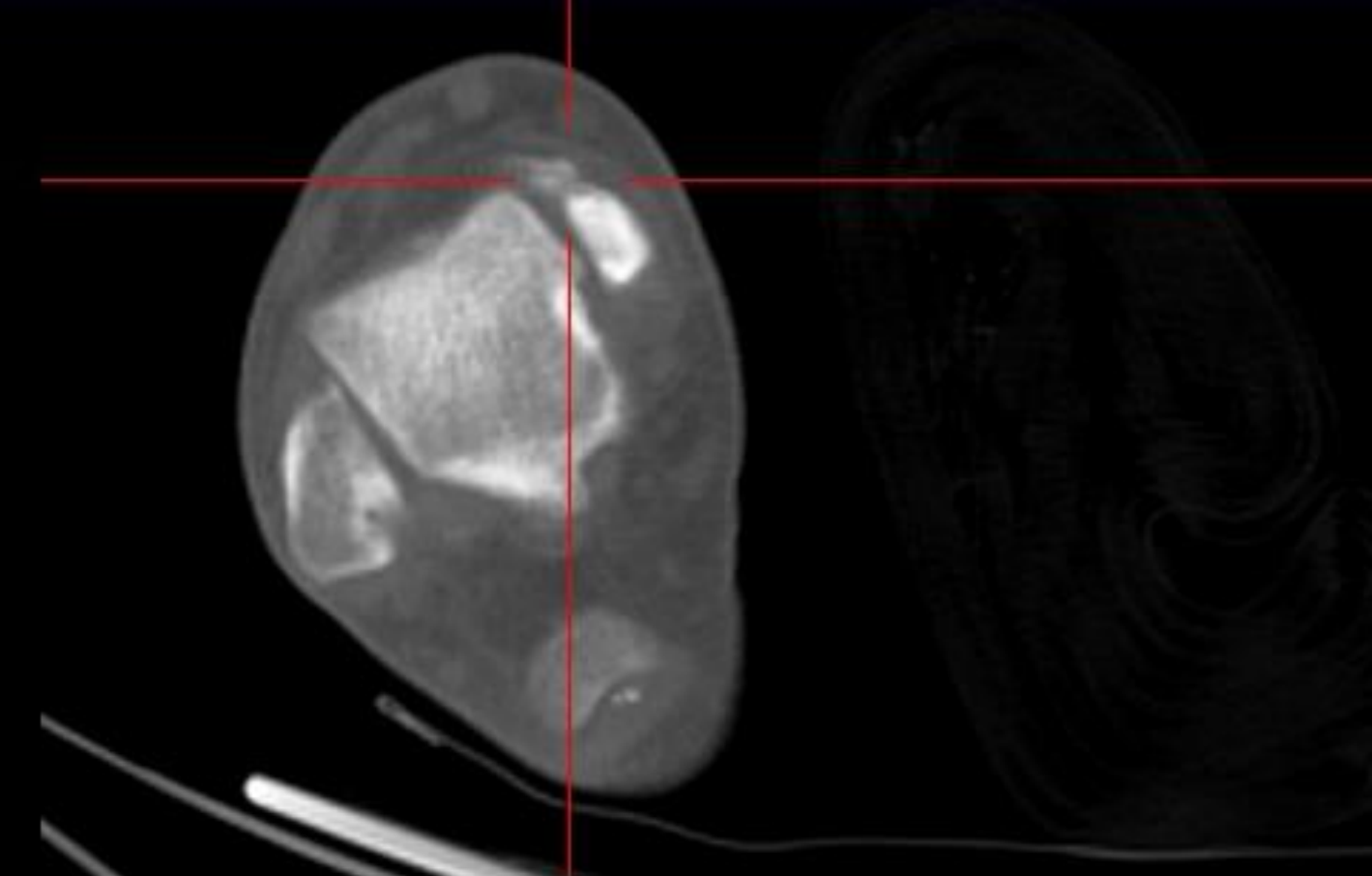
Hyperfixation focale modérée de la pointe de la malléole médiale avec solution de continuité




Stigmates d'arrachement ostéo-ligamentaire post-entorse




HYBRID_CT Sagittals



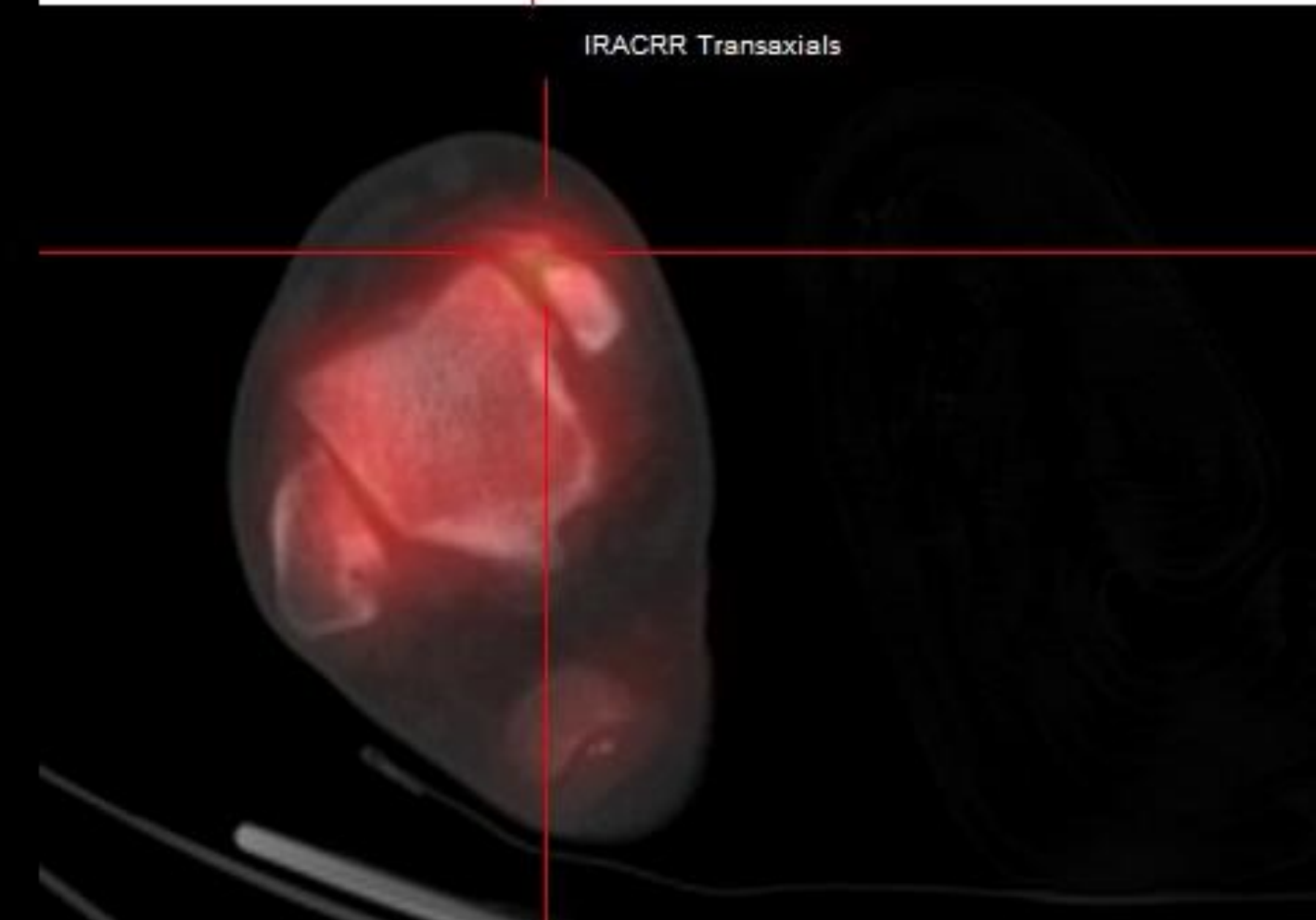
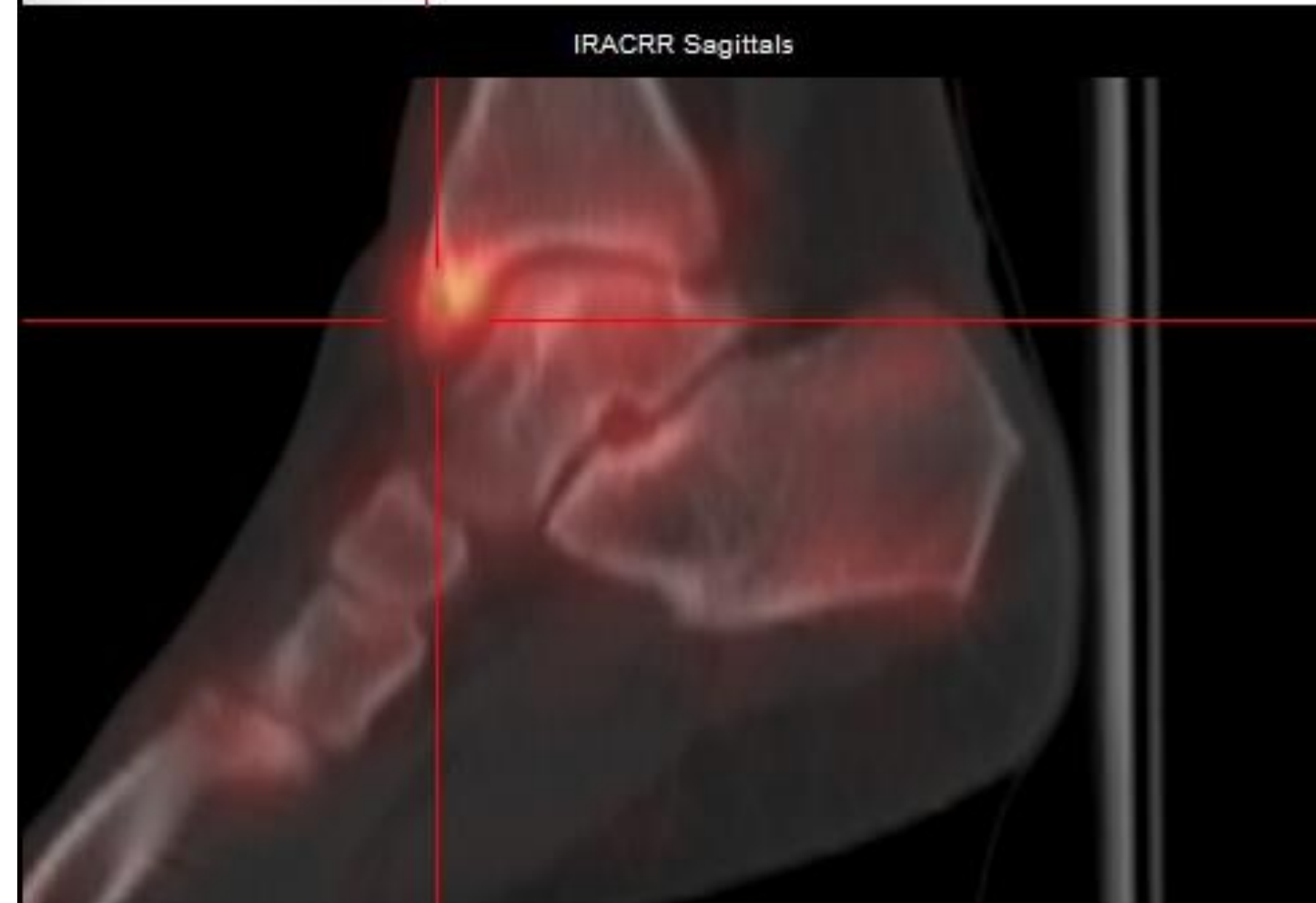
HYBRID_CT Transaxials



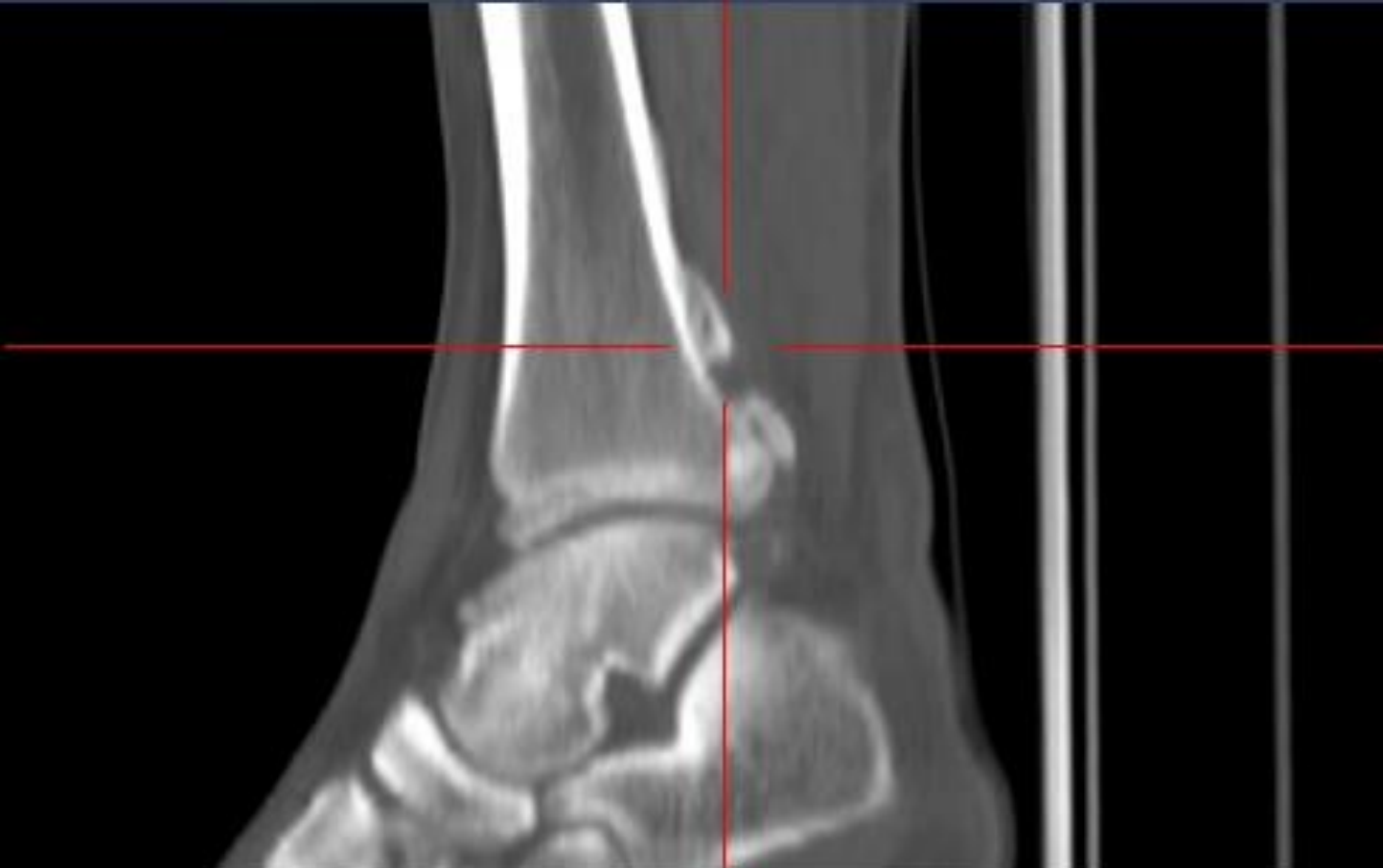IRACRR Sagittals



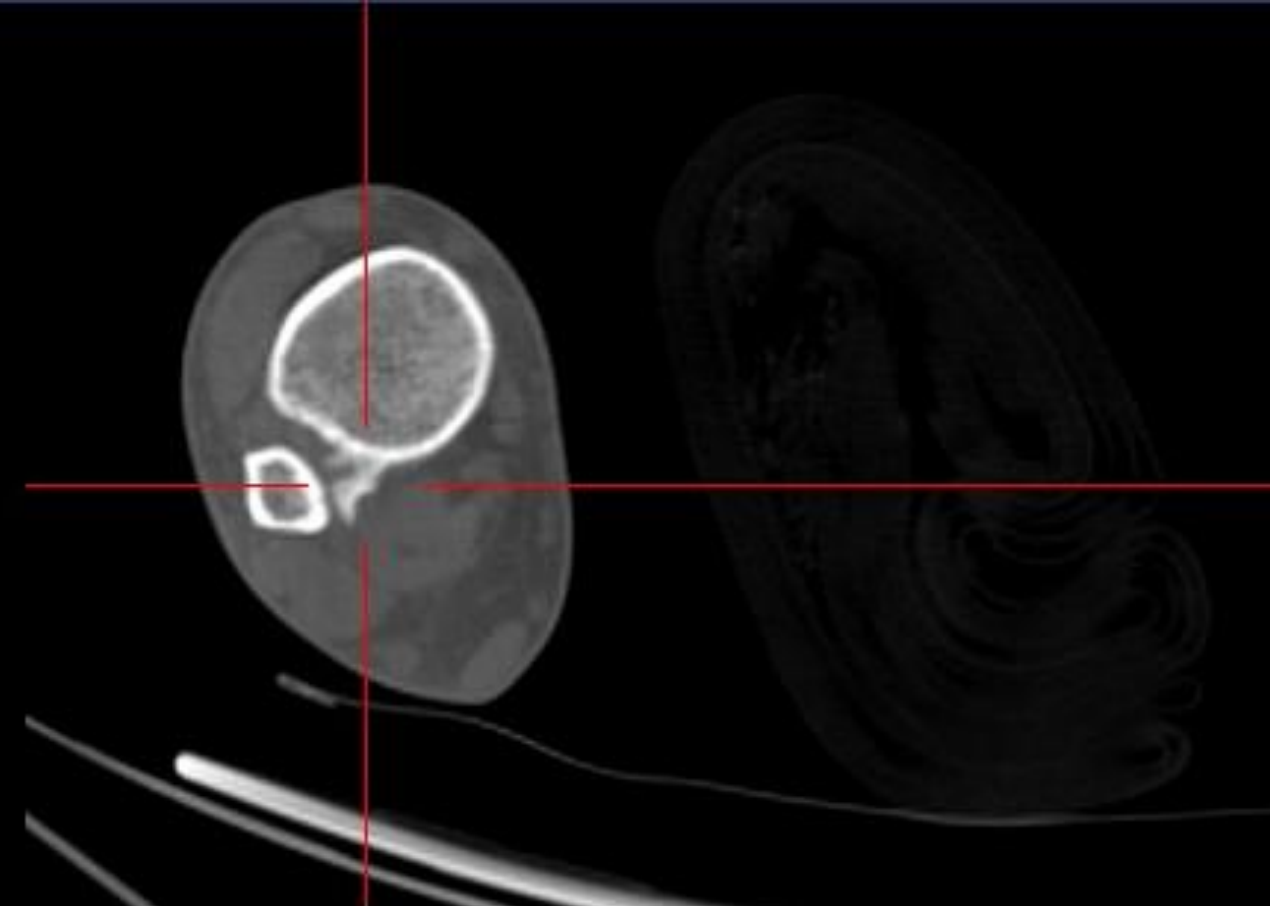
IRACRR Transaxials




CHEVILLE DROITE




HYBRID_CT Sagittals



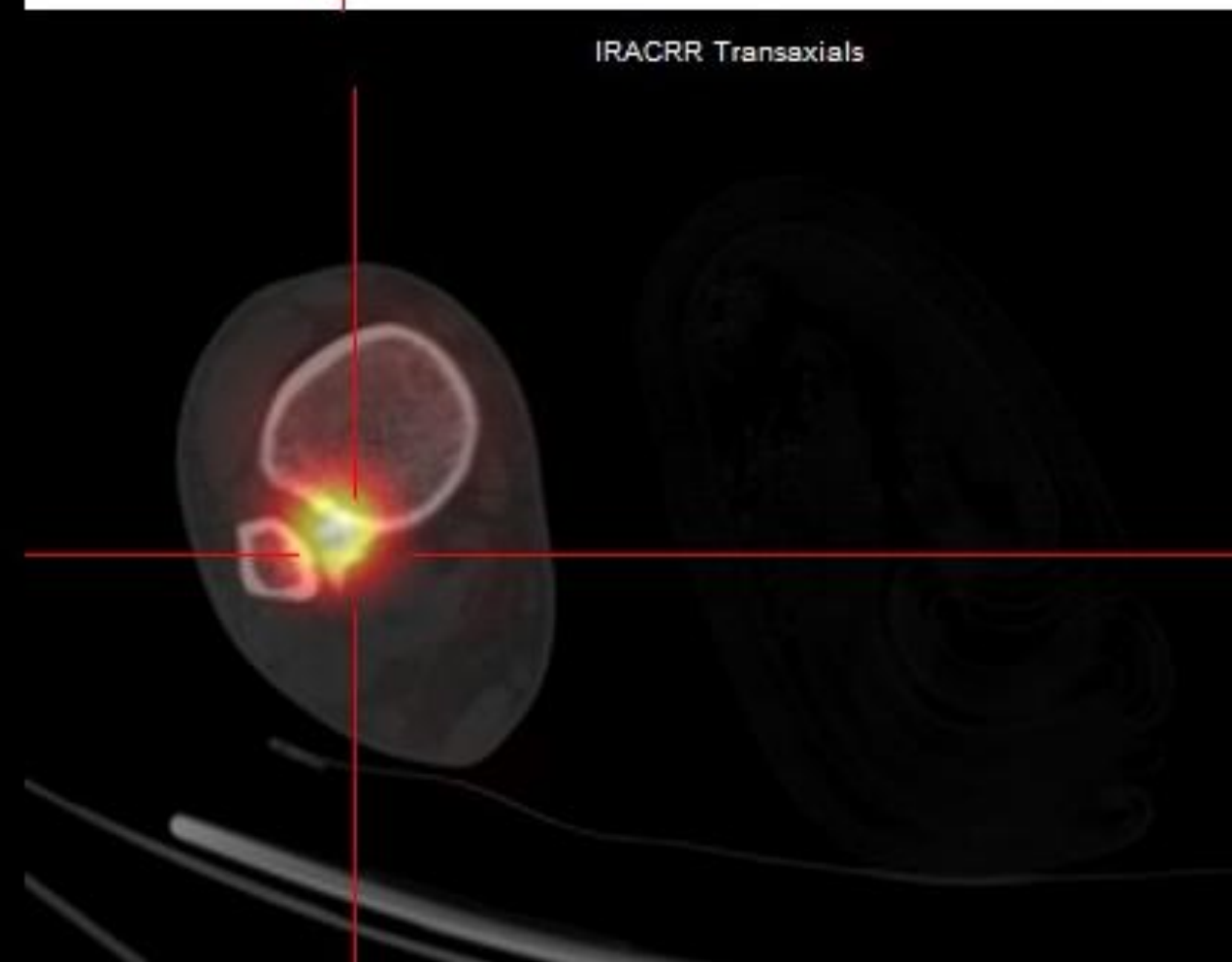
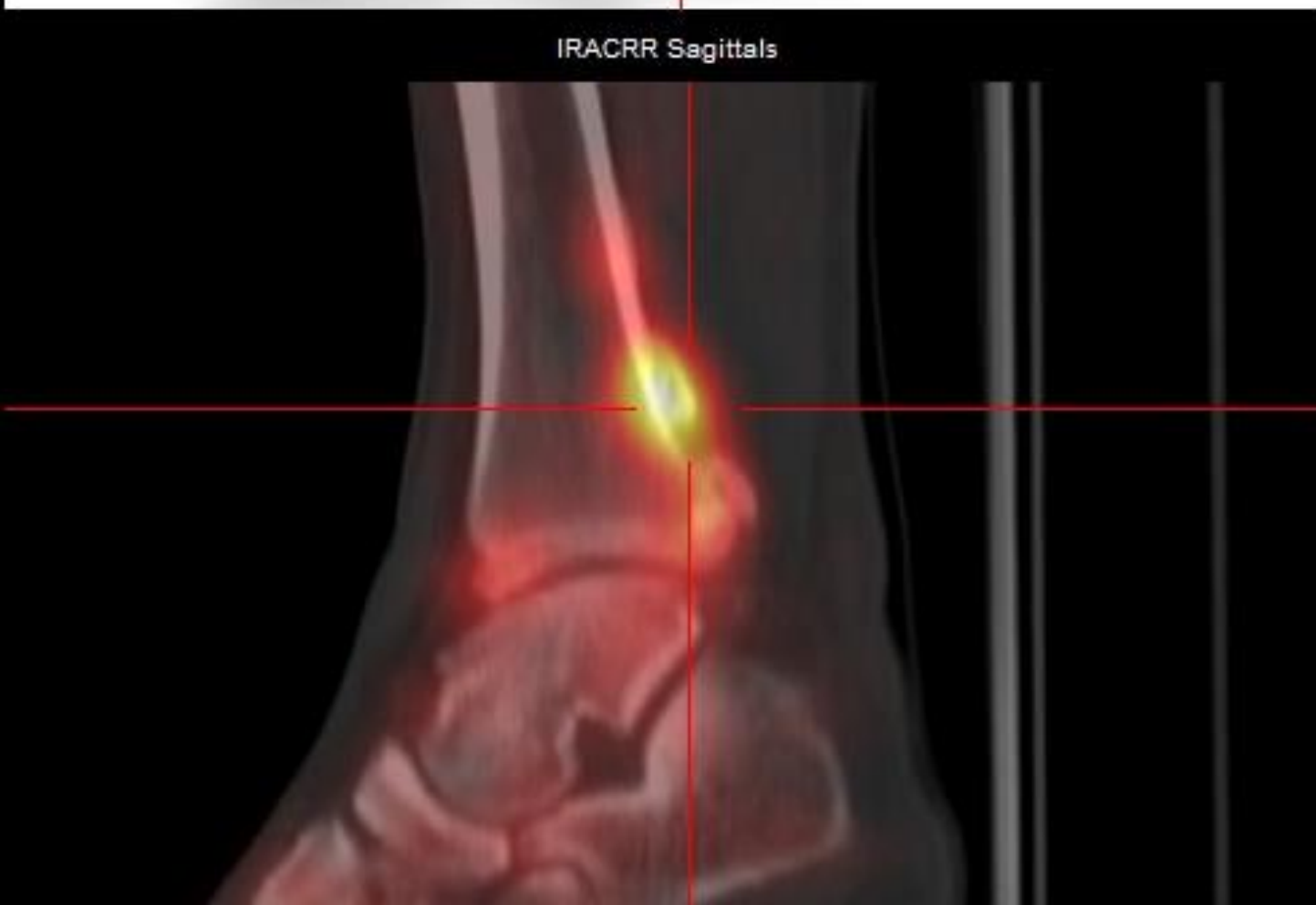HYBRID_CT Transaxials



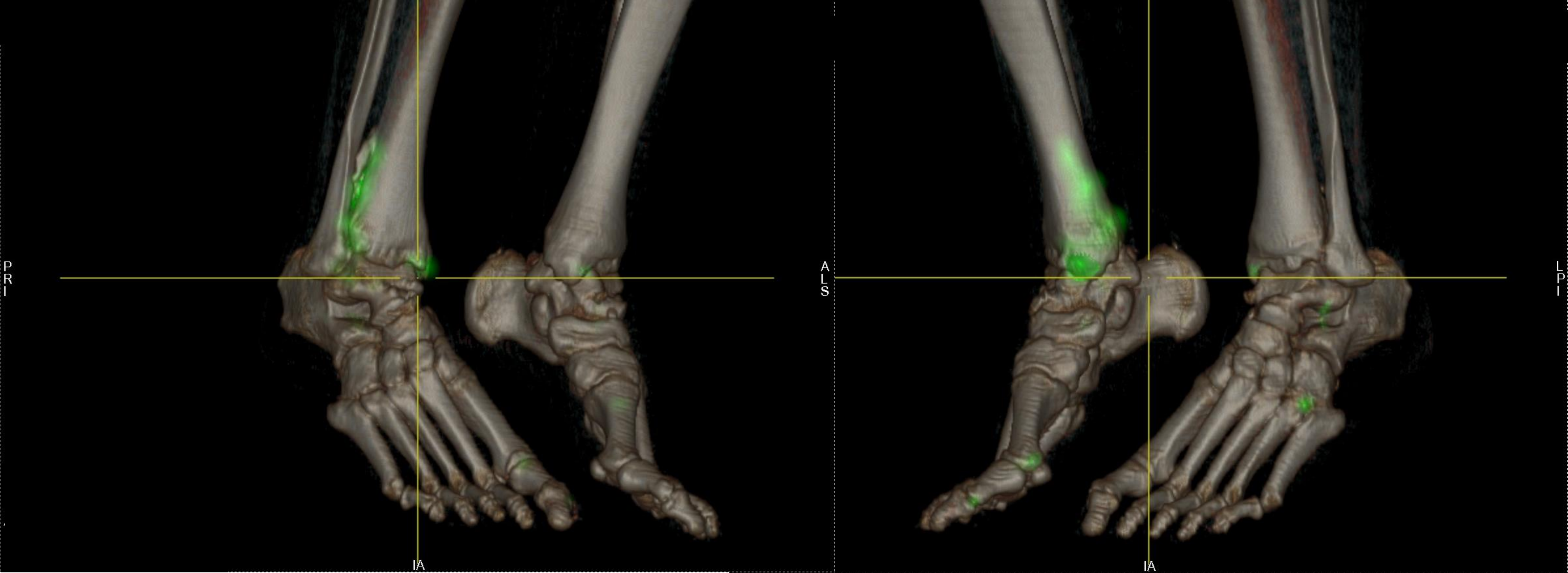IRACRR Sagittals



IRACRR Transaxials



**Calcifications hyperfixantes
hétérogènes de la syndesmose
tibio-fibulaire droite des plans
ligamentaires tibio-fibulaires**



Stigmates d'atteinte ligamentaire tibio-fibulaire droite

Stigmates d'arrachement ostéo-ligamentaire de la malléole médiale droite



IMF