Strange cerebral calcifications ...

CASE REPORT OF THE WEEK

Pierre-Louis Moreau

2020 june

IMF

CASE N° 1

Appearance of an extra-pyramidal syndrome lateralized to the right in a 78-year-old patient.

Decision to perform a presynaptic dopaminergic imaging.

Protocol and Tracer

^{18}F-DOPA PET/CT

18F-DOPA: enzymatic radio-tracer decarboxylated to fluorodopamine after crossing the blood-brain barrier, then stored in the presynaptic neural terminals of the dopaminergic circuits.

Physiological uptake in the striata (caudate nucleus and putamen). Indication: help in the diagnosis of Parkinson's disease and in the distinction between essential tremor and parkinsonian syndromes.

PET images

Homogeneous distribution of the tracer across all striata.

No increase in extra-striatal brain background noise.

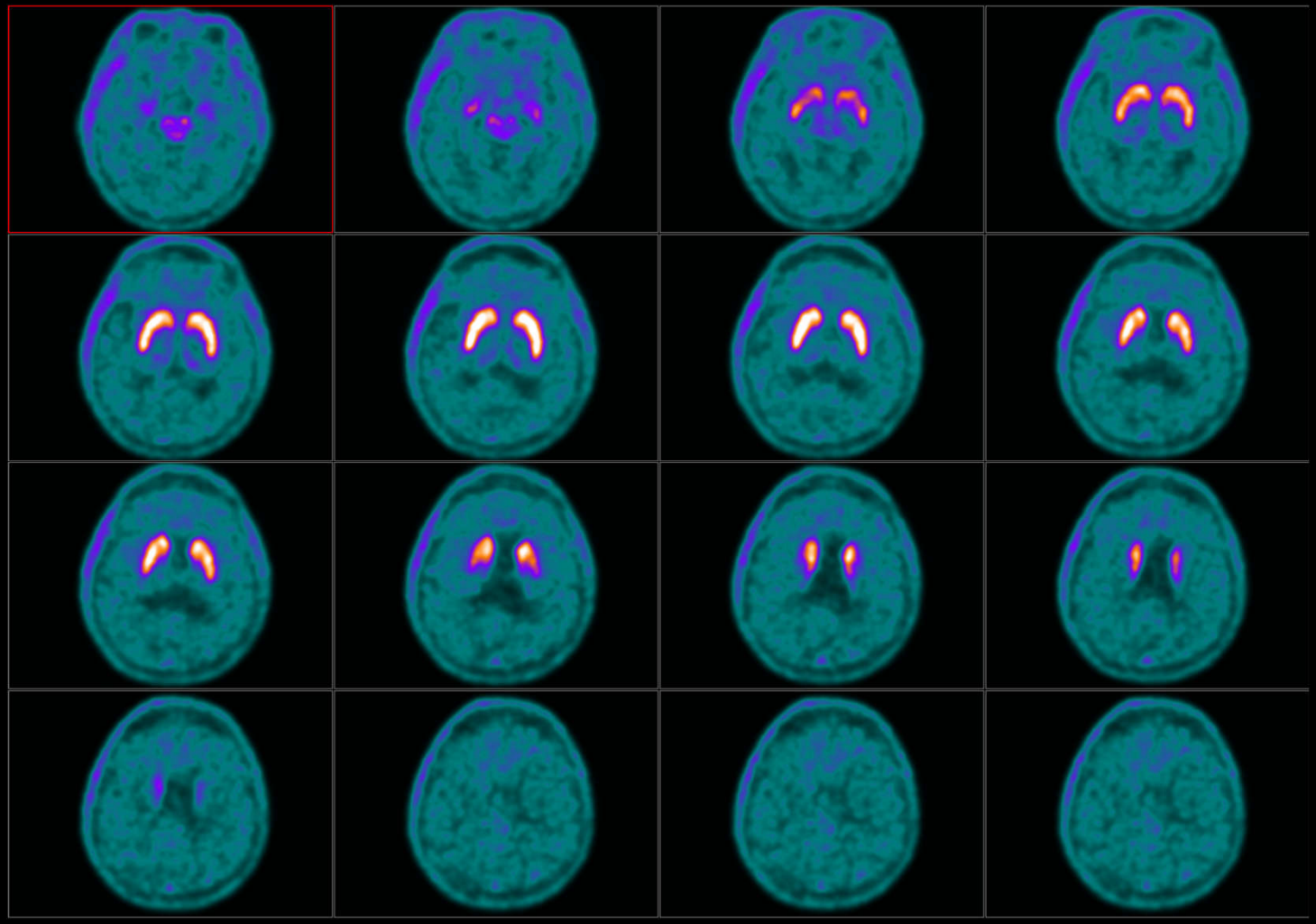

But on the CT images ...

Abnormal striata calcifications!

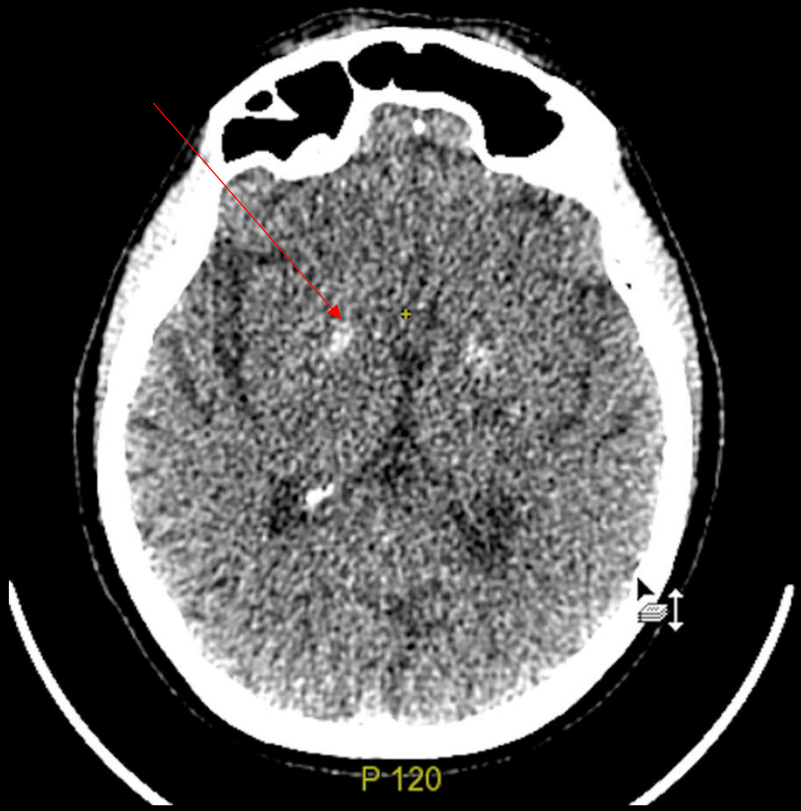

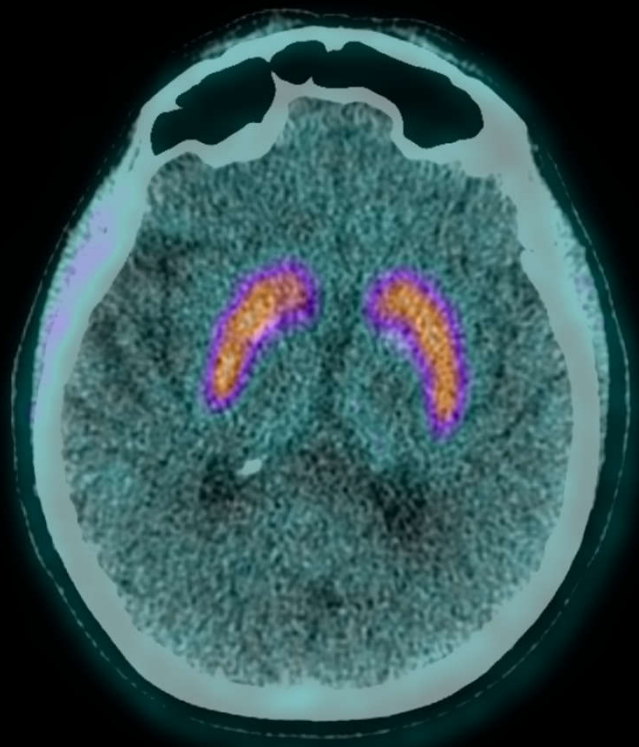

CASE N° 2

Language impairment in a 56-year-old patient

18-FDG brain PET imaging

TEP images

Discreet hypofixation of the pre-frontal cortex with a cortical appearance.

Hypofixation of the basal ganglia and cerebellar hemispheres

Asymmetry of fixation of the lateral temporal cortex on the left side

No significant hypofixation otherwise.

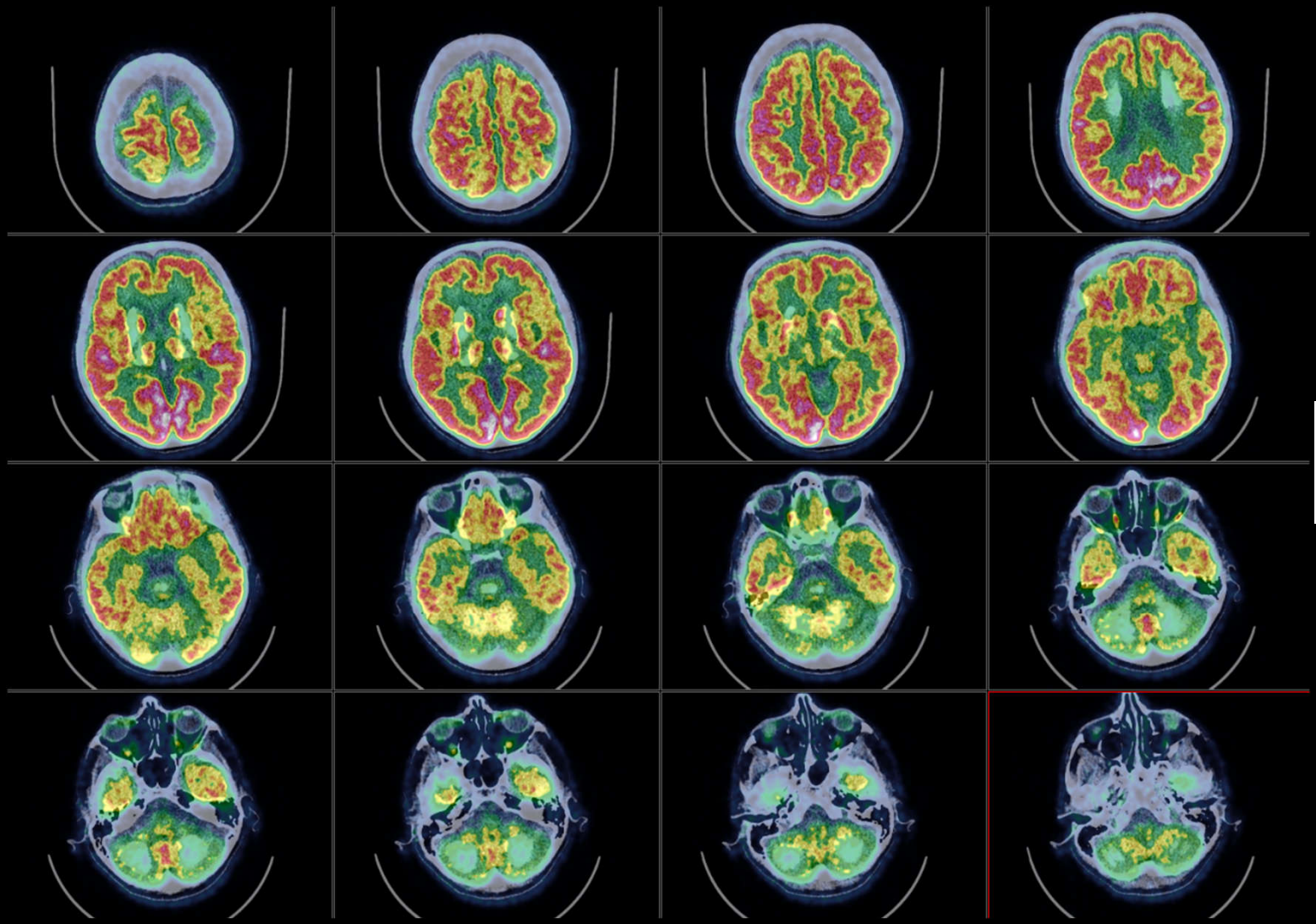

TEP images

Discreet hypofixation of the pre-frontal cortex with a cortical appearance.

Hypofixation of the basal ganglia and cerebellar hemispheres

Asymmetry of fixation of the lateral temporal cortex on the left side

No significant hypofixation otherwise.

Région	Rapport de fix ation	Z-Score
Prefrontal Lateral R	0,97	-3,36
Prefrontal Lateral L	0,96	-3,31
Prefrontal Medial R	0,87	-3,64
Prefrontal Medial L	0,88	-3,25
Sensorimotor R	1,06	2,68
Sensorimotor L	0,99	0,08
Anterior Cingulate R	0,80	-1,38
Anterior Cingulate L	0,84	-0,49
Posterior Cingulate R	1,08	-0,48
Posterior Cingulate L	1,11	0,32
Precuneus R	1,08	-0,22
Precuneus L	1,06	-0,78
Parietal Superior R	0,94	-0,57
Parietal Superior L	0,87	-2,04
Parietal Inferior R	1,05	1,67
Parietal Inferior L	0,97	-1,50
Occipital Lateral R	1,09	2,14
Occipital Lateral L	1,07	1,88
Primary Visual R	1,24	2,02
Primary Visual L	1,21	1,28
Temporal Lateral R	0,96	2,83
Temporal Lateral L	0,91	0,48
Temporal Mesial R	0,75	2,32
Temporal Mesial L	0,77	2,99
Cerebellum Whole	0,56	-4,16
Pons	0,44	-4,78
Région de référence: Global		

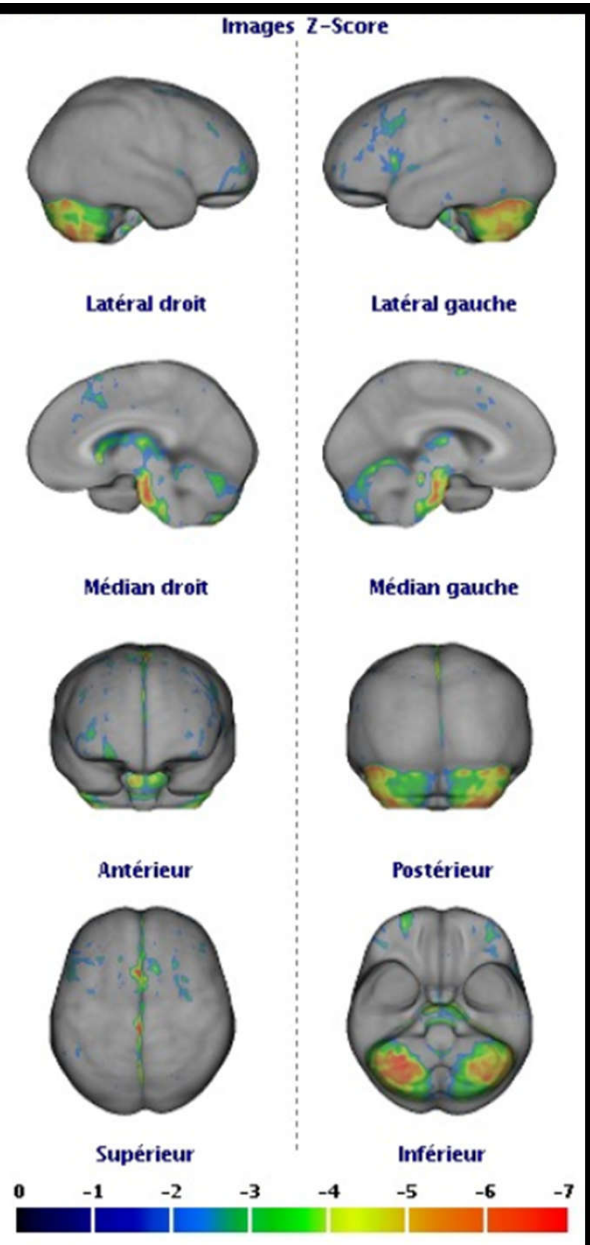

CT images …

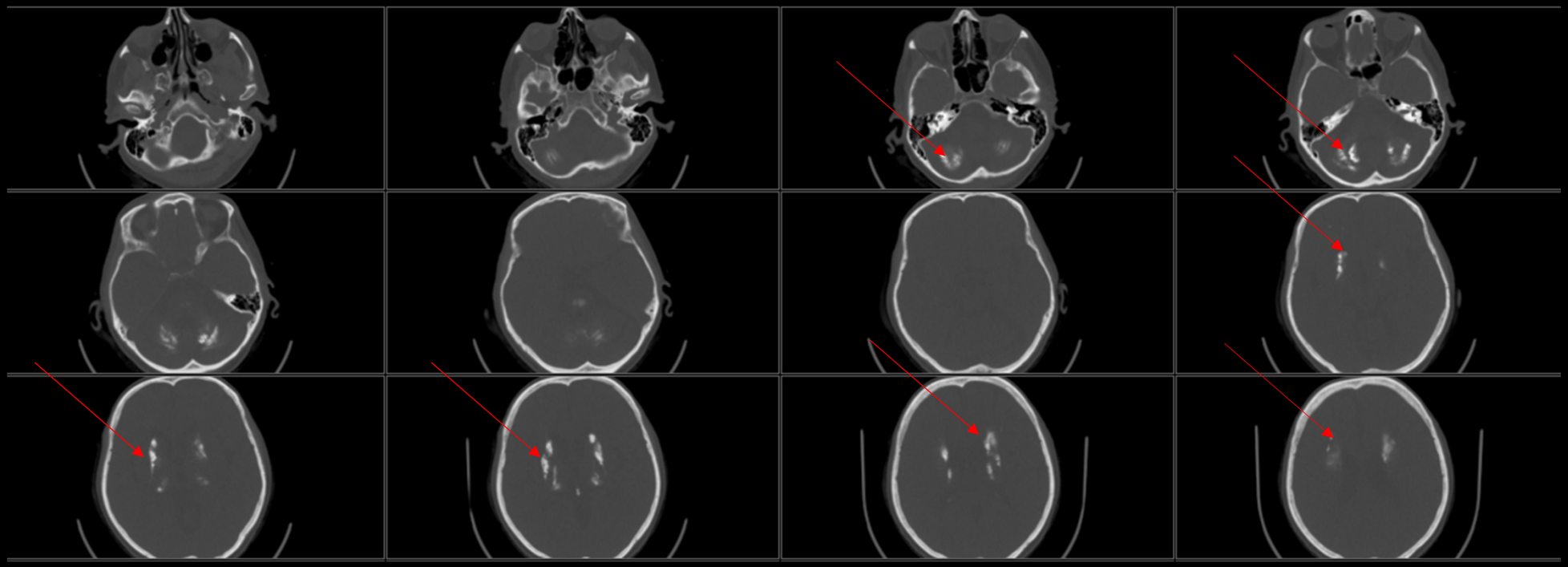

Abnormal mineralization of the basal ganglia, cerebellar hemispheres.

DIAGNOSIS Bilateral striopallidodenteal calcinosis = **Fahr's disease**

- Also known as Fahr's disease
- Less than 200 cases reported, sex ratio M / F = 2/1.
- Idiopathic or familial (autosomal dominant transmission, genes not known).
- Sometimes secondary to hypoparathyroidism (primary or postoperative).

Source : Orphanet

DIAGNOSIS Bilateral striopallidodenteal calcinosis = Fahr's disease

- **Clinic:** symptoms usually starting from the age of 40:
  - progressive movement disorders such as parkinsonian syndrome, chorea, dystonia, ataxia,
  - neuropsychiatric disorders
  - Dementia.

Source : Orphanet

DIAGNOSIS Bilateral striopallidodenteal calcinosis = Fahr's disease

- **CT and MRI morphological diagnosis:**
  - bilateral, almost symmetrical calcifications of one or more of the following areas: basal ganglia, dentate nucleus, thalamus, cerebellum and cerebral white matter.

- **TEMP / PET**
  - bilateral decrease in perfusion / metabolism of the basal ganglia and the cerebral cortex.

Source : Orphanet


IMF